

INTESTINAL VASCULITIS AS A MANIFESTATION OF DIFFERENT SYSTEMIC AUTOIMMUNE DISEASES TREATED AT THE SPLIT UNIVERSITY HOSPITAL CENTRE DURING A 10-YEAR PERIOD

VASKULITISI CRIJEVA KAO OČITOVANJA RAZNIH SUSTAVNIH AUTOIMUNIH BOLESTI LIJEČENI U KLINIČKOM BOLNIČKOM CENTRU SPLIT U DESETOGODIŠNJEM RAZDOBLJU

Daniela Marasović Krstulović^{1,2}, Petra Šimac¹, Dijana Perković^{1,2}, Dušanka Martinović Kaliterna²

¹Division of Rheumatology and Clinical Immunology, Department of Internal Medicine, Split University Hospital Centre, Spinčićeva 1, Split, Croatia

/ Zavod za kliničku imunologiju i reumatologiju, Klinika za unutarnje bolesti, Klinički bolnički centar Split, Split, Hrvatska

²School of Medicine, University of Split, Šoltanska 2, Split, Croatia

/ Medicinski fakultet Sveučilišta u Splitu, Split, Hrvatska

Corresponding author / Adresa autora za dopisivanje:

Petra Šimac, dr. med.

Division of Rheumatology and Clinical Immunology / Zavod za kliničku imunologiju i reumatologiju

Department of Internal Medicine / Klinika za unutarnje bolesti

Split University Hospital Centre / Klinički bolnički centar Split

Spinčićeva 1, 21 000, Split

Croatia / Hrvatska

Phone / tel.: +385 21 557 630

E-mail / e-pošta: psimacr@gmail.com

Received / Primljeno: April 19, 2021 / 19. 4. 2021.

Accepted / Prihvaćeno: June 13, 2021 / 13. 6. 2021.

ABSTRACT

Introduction. The most common types of vasculitis that involve the gastrointestinal tract (GIV) are immune complex-mediated in systemic lupus erythematosus (SLE), Sjögren's syndrome (SS), mixed connective tissue disease (MCTD), and IgA vasculitis (IgAV). GI manifestations are rarely the leading symptom of systemic vasculitis. Only 1 – 5% of rheumatoid arthritis (RA) patients develop symptoms of gastrointestinal tract vasculitis (GIV), while up to 40% of them have GI symptoms. GIV is a rare but life-threatening complication in patients with SLE with a prevalence of up to 2.5%. The leading symptoms in patients with GIV include abdominal pain, nausea, vomiting, diarrhoea, small bowel obstruction, and profuse GI bleeding. The objective of this study was to describe the incidence and clinical manifestations of GIV in patients with various systemic autoimmune (AI) diseases who were treated at Split University Hospital Centre over a 10-year period. **Materials and methods.** A retrospective study was conducted by analysing medical records of patients diagnosed with GIV and treated for SLE, SS, MCTD, vasculitis syndrome, IgAV, and RA between January 2009 and December 2018. Only patients with anamnestic data in relation to abdominal pain or endoscopic and/or radiographic findings of GIV were included in the study. **Results.** Out of a total number of 12 patients with a confirmed diagnosis of GIV, 9 were male. Eight of them had vasculitis with gastrointestinal involvement (GIV) in IgAV, 2 patients had GIV in SLE, 1 patient had microscopic polyangiitis (MPA), and one patient had primary SS. In 6 cases, GIV was diagnosed by an MSCT of the abdomen, in one case it was diagnosed by a PET-CT scan, in another case it was diagnosed through histopathological findings, and in 4 cases it was diagnosed through endoscopic findings. The leading symptom in 4 patients was abdominal pain with nausea and vomiting, 2 had profuse GI bleeding, 1 had fatigue without GI symptoms, and the remaining patients' clinical features included acute abdomen with visible radiographic thickening of the bowel wall with oedema and stratification with ascites. GIV was the cause of death of one patient with SLE. Others had a good or moderate response to treatment with glucocorticoids and immunosuppressants. **Conclusion.** In conclusion, GIV is a rare manifestation of systemic AI diseases, but the clinical features can be very severe and lead to a fatal outcome, especially if it is not diagnosed at an early stage and treated with aggressive immunosuppressive therapy.

KEY WORDS: Vasculitis; Gastrointestinal; Mesenteric; IgA vasculitis; Autoimmune diseases

SAŽETAK

Uvod. Najčešći vaskulitisi gastrointestinalnog trakta (GIV) su oni posredovani imuno-kompleksima u sistemskom eritemskom lupusu, Sjögrenovoj bolesti, miješanoj bolesti vezivnog tkiva, IgA-vaskulitisu (IgAV). Gastrointestinalne (GI) manifestacije rijetko su vodeći simptom sustavnih vaskulitisa. Samo 1–5% bolesnika s reumatoidnim artritisom razvija kliničku sliku vaskulitisa gastrointestinalnoga trakta (GIV), dok ih do 40% ima GI simptome. GIV je rijetka, ali životno ugrožavajuća komplikacija u bolesnika sa sistemskim eritemskim lupusom (SLE), s prevalencijom do 2,5%. Vodeći simptomi u bolesnika s GIV-om su bol u trbuhu, mučnina, povraćanje, proljev, opstrukcija tankog crijeva i obilno GI krvarenje. Cilj ovog rada bio je ispitati učestalost i klinička očitovanja GIV-a u bolesnika s različitim sustavnim autoimunim (AI) bolestima liječenih u KBC-u Split u desetogodišnjem razdoblju. **Materijali i metode.** Retrospektivno su analizirani podaci iz medicinske dokumentacije bolesnika koji su se liječili od SLE-a, Sjögrenovog sindroma (SjS), miješane bolesti vezivnog tkiva (MCTD), sindroma vaskulitisa, IgA-vaskulitisa (IgAV) i RA, a imali su anamnestičke podatke o boli u trbuhu ili endoskopske ili/i radiografske znakove GIV-a, u razdoblju od 1/2009. do 12/2018. **Rezultati.** Od ukupno 12 bolesnika s potvrđenom dijagnozom GIV-a, 9 su bili muškarci. Osam ih je imalo GIV u sklopu IgAV-a, dvije bolesnice u sklopu SLE-a, MPA jedna bolesnica, primarnog SS-a jedan bolesnik. U 6 slučajeva GIV je dokazan MSCT-om trbuha, u jednom PET-CT-om, u jednom patohistološki, a u 4 slučaja endoskopski. Vodeći simptom u četvero bolesnika bila je bol u trbuhu s mučninom i povraćanjem, dva su imala su obilno GI krvarenje, jedna bolesnica je imala umor bez GI simptoma, a preostali kliničku sliku akutnog abdomena s radiološki verificiranim edemom i raslojavanjem stijenke crijeva uz ascites. GIV je bio uzrok smrti jedne bolesnice sa SLE-om. Ostali su imali dobar ili umjeren odgovor na liječenje glukokortikoidima i imunosupresivima. **Zaključak.** Zaključno, GIV je rijetka manifestacija sustavnih AI bolesti, ali klinička slika može biti vrlo teška i dovesti do fatalnog ishoda te je nužna brza dijagnoza i agresivno imunosupresivno liječenje.

KLJUČNE RIJEČI: Vaskulitis; Gastrointestinalni; Mezenterijalni; IgA-vaskulitis; Autoimune bolesti

INTRODUCTION

Systemic autoimmune (AI) diseases can cause various gastrointestinal (GI) disorders, some of which may be the first symptom of the disease and some a consequence of underlying disease treatment (1). Rare but potentially fatal GI manifestations of AI diseases, which require timely and rapid care, are vasculitides of the GI tract (gastrointestinal vasculitis, GIV). Vasculitis is an inflammation of the walls of blood vessels with or without necrosis and granuloma. The diagnosis of different forms of GIV is based on a combination of clinical features and available tests (endoscopy, computed tomography (CT), magnetic resonance imaging (MRI), histopathology diagnosis). It is crucial to make a correct diagnosis given the different approaches to treatment, but also the prognosis that varies greatly depending on the type of disorder (2). GI blood vessels can be affected in various types of vasculitis affecting large, medium and small blood vessels and those of variable size according to the 2012 Revised International Chapel Hill classification (Table 1) (3). The GI tract (GIT) may be the primary site of involvement of several systemic vasculitides: Henoch–Schönlein purpura (IgA vasculitis, IgAV), polyarteritis nodosa (PAN), eosinophilic granulomatosis with polyangiitis (EGPA), microscopic polyangiitis (MPA), granulomatosis with polyangiitis (GPA), Behçet's disease, systemic lupus erythematosus (SLE), mixed connective tissue disease (MCTD), systemic sclerosis (SSc). The most common types of vasculitides that involve the GIT tract are: SLE, MCTD and IgAV (2). GIV is almost just

UVOD

Sistemske autoimune (AI) bolesti mogu uzrokovati čitav spektar različitih gastrointestinalnih (GI) poremećaja od kojih neki mogu biti prvi simptom bolesti, a neki posljedica liječenja osnovne bolesti (1). Rijetke, ali potencijalno fatalne GI manifestacije AI bolesti, koje zahtijevaju pravodobno i brzo zbrinjavanje, upravo su vaskulitisi GI trakta (engl. *gastrointestinal vasculitis*, GIV). Vaskulitis je upala stijenke krvne žile s nekrozom i granulomom ili bez njih. Dijagnoza različitih oblika GIV-a temelji se na kombinaciji kliničke slike i dostupnih pretraga (endoskopija, kompjuterizirana tomografija [engl. *computed tomography*, CT], magnetska rezonancija [engl. *magnetic resonance imaging*, MRI], patohistološka dijagnostika [PHD]). Od ključne je važnosti postaviti ispravnu dijagnozu s obzirom na različite pristupe u liječenju, ali i prognoze koji se uvelike razlikuju ovisno o vrsti poremećaja (2). GI krvožilje može biti zahvaćeno kod raznih tipova vaskulitisa koji pogađaju velike, srednje i male krvne žile te one promjenjive veličine sukladno Chapel Hill klasifikaciji revidiranoj 2012. (tablica 1) (3). GI trakt (GIT) može biti primarno mjesto zahvaćanja nekoliko sistemskih vaskulitisa: Henoch-Schönleinova purpura (IgA-vaskulitis, IgAV), nodozni poliarteritis (engl. *polyarteritis nodosa*, PAN), eozinofilna granulomatoza s poliangiitismom (engl. *eosinophilic granulomatosis with polyangiitis*, EGPA), mikroskopski poliangiitis (engl. *microscopic polyangiitis*, MPA), granulomatoza s poliangiitismom (engl. *granulomatosis with polyangiitis*, GPA),

TABLE 1. Classification of vasculitis according to 2012 Chapel Hill Classification (according to reference no. 3)
 TABLICA 1. Klasifikacija vaskulitisa prema reviziji Chapel Hill klasifikacije iz 2012. godine (prema referenciji br. 3)

Large-vessel vasculitis / Vaskulitis velikih krvnih žila	Giant cell arteritis / Gigantocelularni (temporalni) Takayasu's arteritis / Takayasuov arteritis
Medium-vessel vasculitis / Vaskulitis srednje velikih krvnih žila	Polyarteritis nodosa / Nodozni poliarteritis
Small-vessel vasculitis / Vaskulitis malenih krvnih žila	Kawasaki disease / Kawasakijska bolest ANCA-associated vasculitis / ANCA-vaskulitis <ul style="list-style-type: none"> - Microscopic polyangiitis (MPA) / mikroskopski poliangiitis (MPA) - Granulomatosis with polyangiitis (GPA) / Granulomatoza s poliangiitisom (GPA) - Eosinophilic granulomatosis with polyangiitis (EGPA) / Eozinofilna granulomatoza s poliangiitisom (EGPA) Immune complex vasculitis / Vaskulitis imunih kompleksa <ul style="list-style-type: none"> - Anti-glomerular basement membrane (anti-GBM) disease / Anti-GBM vaskulitis - Cryoglobulinemic vasculitis / Krioglobulinemički vaskulitis - IgA vasculitis (Henoch-Schönlein) / IgA-vaskulitis (Henoch-Schönlein) - Hypocomplementemic urticarial vasculitis (HUV) (anti-C1q vasculitis) / Hipokomplementemički urtikarijalni vaskulitis (anti-C1q-vaskulitis)
Variable-vessel vasculitis / Vaskulitis različito velikih krvnih žila	Behçet's disease / Behçetova bolest Cogan's syndrome / Coganov sindrom
Single-organ vasculitis / Vaskulitis jednog organa	Cutaneous leukocytoclastic angiitis / Kožni leukocitoklastički angiitis Cutaneous arteritis / Kožni arteritis Primary CNS vasculitis / Primarni vaskulitis SŽS-a Isolated aortitis / Izolirani aortitis Others / Drugo
Vasculitis associated with systemic disease / Vaskulitis udružen sa sistemskom autoimunom bolešću	Lupus vasculitis / Lupusni vaskulitis Rheumatoid vasculitis / Reumatoidni vaskulitis Sarcoid vasculitis / Vaskulitis u sarkoidozi Others / Drugo
Vasculitis associated with systemic disease / Vaskulitis udružen s drugim bolestima	Hepatitis C virus-associated cryoglobulinemic vasculitis / Krioglobulinemički vaskulitis uz infekciju HCV-om Hepatitis B virus-associated vasculitis / Vaskulitis uz infekciju HBV-om Syphilis-associated aortitis / Aortitis udružen sa sifilisom Drug-associated immune complex vasculitis / Vaskulitis imunih kompleksa uzrokovan lijekovima Drug-associated ANCA-associated vasculitis / ANCA-vaskulitis uzrokovan lijekovima Cancer-associated vasculitis / Vaskulitis uz malignu bolest Others / Drugo

Legend / Legenda: ANCA – antineutrophil cytoplasmic antibodies / antineutrofilna citoplazmatska antitijela; GBM – glomerular basement membrane / glomerularna bazalna membrana; CNS / SŽS – central nervous system / središnji živčani sustav; HCV – hepatitis C virus / virus hepatitisa C; HBV – hepatitis B virus / virus hepatitisa B.

as often induced by drugs and GI infections (due to glucocorticoid [GC]-induced immunosuppression) (4). The pathophysiological mechanism of most gastrointestinal vasculitides (GIVs) is immune-mediated by the deposition of autoantibody and antigen complexes or antibody complexes, as well as the direct action of antibodies. In some cases, a cell-mediated allograft rejection reaction occurs (1,4). In case of some diseases, such as Takayasu's arteritis (TAK) or polyarteritis nodosa (PAN), the pathophysiological mechanism is still not completely clear (4).

The clinical course as well as pathological changes in GIV are highly variable and depend on the type of vascular lesions (localised or diffuse) of the GI tract. Accordingly, GIT lesions in vasculitis include ulcers, submucosal oedema, haemorrhage, paralytic ileus, mesen-

Behçetova bolest, sistemski eritemski lupus (engl. *systemic lupus erythematosus*, SLE), miješana bolest vezivnog tkiva (engl. *mixed connective tissue disease*, MCTD), sistemska skleroza (engl. *systemic sclerosis*, SSc). Od navedenih, GIT najčešće zahvaćaju: SLE, MCTD i IgAV (2). Gotovo jednako često GIV je induciran lijekovima te GI infekcijama (uslijed glukokortikoidno [GK] uzrokovane imunosupresije) (4). Patofiziološki mehanizam većine GIV-a je imunološki posredovan odlaganjem kompleksa autoprotutijela i antigena ili samih protutijela, kao i direktnim djelovanjem protutijela. U nekim slučajevima dolazi do stanično posredovane reakcije odbacivanja alotransplantata (1,4). Za neke bolesti, poput Takayasuova arteritisa (TAK) ili nodoznog poliarteritisa (PAN), patofiziološki mehanizam još uvijek nije u potpunosti jasan (4).

teric ischaemia, bowel obstruction, and perforation (5,6,7). Clinical manifestations range from abdominal pain (sometimes cramping), which usually gets worse after eating, to obvious signs of intestinal ischaemia or bowel perforation with diffuse and constant abdominal pain, slow peristalsis, guarding and distension, and signs of peritoneal irritation. GI bleeding, often occult, hematochezia, and less frequently melena or rectorrhagia, are common occurrences. Non-specific symptoms such as nausea, vomiting or diarrhoea may also occur. Furthermore, pancreatitis, cholecystitis or appendicitis may rarely occur (8).

GIT involvement in large-vessel vasculitis is not a common occurrence. Takayasu's arteritis is a type of vasculitis that commonly affects the celiac plexus and hepatic or mesenteric arteries, with clinically significant consequences in about 16% of patients, while only 4% of patients develop mesenteric ischaemia (4,9). Half of patients with polyarteritis nodosa (PAN) develop GIV, which can manifest as acute abdominal pain, GI bleeding, infarction, peritonitis, cholecystitis, appendicitis, and perforation (4). Up to 60% of patients with Kawasaki disease may have GI symptoms (abdominal pain, vomiting), but these symptoms are severe in only 4.6% of patients (10).

When it comes to antineutrophil cytoplasmic antibody (ANCA)-associated vasculitides (AAV), GIT involvement is more common in eosinophilic granulomatosis with polyangiitis (EGPA) (35 – 50%) in comparison with microscopic polyangiitis (MPA) (5 – 30%) or granulomatosis with polyangiitis (GPA) (5 – 10%). The leading GI symptoms in patients with EGPA are abdominal pain, bloody diarrhoea (30 – 58%), vomiting, ileus, anorexia, GI bleeding (29%), and odynophagia. Patients with GPA have similar symptoms, with possible intestinal perforation and/or ischaemia and granulomatous hepatitis or pancreatitis. Symptoms of GIV in patients with MPA range from abdominal pain, nausea, vomiting, and diarrhoea to, rarely, ischaemic colon ulcers, peritonitis, and bowel perforation (2,4).

GI symptoms in IgAV are varied and very common (50 – 85% of patients) and they include: diarrhoea, vomiting, abdominal pain, obstruction, perforation, distension, intussusception, haematemesis, melena, and hematochezia. The inferior part of the duodenum is predominantly affected. In approximately 14% of cases, GIV is the first manifestation of IgAV (11,12). There are two types of GIV in Behçet's disease that can develop in 3 – 50% of patients. If small blood vessels are affected, inflammation of the intestinal mucosa with ulcerations occurs, and if large-vessel vasculitis develops, ischaemia and infarction of the bowel wall can occur (13,14).

Various GI manifestations may occur in patients with SLE (up to 40%), including lupus peritonitis, non-

Klinički tijek kao i patološke promjene u GIV-u jako su varijabilni te ovise o vrsti oštećenja GI krvnožilja (lokalno ili difuzno). Sukladno tomu, lezije GIT-a u vaskulitisu uključuju ulkuse, submukozni edem, krvarenje, paralitički ileus, ishemiju mezenterija, opstrukciju crijeva i perforaciju (5,6,7). Kliničke manifestacije variraju od boli u trbuhu (ponekad grčevite), koja se obično pogoršava nakon jela, do očitih znakova ishemije ili perforacije crijeva uz difuznu i konstantnu trbušnu bol, usporenu peristaltiku, „defans“ i distenziju te znakove peritonealnog nadražaja. GI krvarenje, često okultno, hematokezija te rjeđe melena ili rektorigija, učestale su pojave. Također se mogu pojaviti i nespecifični simptomi poput mučnine, povraćanja ili proljeva. Nadalje, rijetko može doći i do pojave pankreatitisa, kolecistitisa ili apendicitisa (8).

Zahvaćenost GIT-a u vaskulitisima velikih krvnih žila nije česta pojava. GIV u sklopu TAK-a najčešće zahvaća celijski pleksus te hepatalne ili mezenterične arterije, s klinički značajnim posljedicama u oko 16% bolesnika, dok se u svega 4% bolesnika razvija ishemija mezenterija (4,9). U polovici oboljelih od PAN-a dolazi do razvoja GIV-a koji se može očitovati kao akutna trbušna bol, GI krvarenje, infarkcija, peritonitis, kolecistitis, apendicitis i perforacija (4). Do 60% bolesnika s Kawasakijskom bolešću može imati GI simptome (trbušna bol, povraćanje), ali ti su simptomi ozbiljni samo kod njih 4,6% (10).

Među vaskulitisima udruženim s antineutrofilnim citoplazmatskim antitijelima (engl. *ANCA associated vasculitis*, AAV) zahvaćenost GIT-a je češća u EGPA (35–50%), u usporedbi s MPA (5–30%) ili GPA (5–10%). Vodeći GI simptomi u bolesnika s EGPA su trbušna bol, krvavi proljevi (30–58%), povraćanje, ileus, anoreksija, GI krvarenje (29%) te odinofagija. Slične simptome imaju i bolesnici s GPA uz moguću perforaciju ili/i ishemiju crijeva te granulomatozni hepatitis ili pankreatitis. Simptomi GIV-a u bolesnika s MPA kreću se u rasponu od trbušne boli, mučnine, povraćanja i proljeva do, rijetko, ishemijskih ulkusa kolona, peritonitisa i perforacije crijeva (2,4).

GI simptomi u IgAV-u su raznovrsni i vrlo česti (50–85% bolesnika): proljev, povraćanje, grčevita bol u trbuhu, opstrukcija, perforacija, distenzija, intususcepcija, hematemeza, melena, hematokezija. Dominantno je zahvaćen donji dio duodenuma. U otprilike 14% slučajeva, GIV je prva manifestacija IgAV-a (11,12). Dva su tipa GIV-a u Behçetevoj bolesti koja se mogu razviti u 3–50% oboljelih. Ukoliko su zahvaćene male krvne žile, dolazi do upale crijevne mukoze s ulceracijama, a ukoliko se radi o vaskulitisu velikih krvnih žila može doći do ishemije i infarkta crijevne stijenke (13,14).

U bolesnika sa SLE-om mogu se javiti raznovrsne GI manifestacije (do 40%), uključujući lupus peritonitis,

necrotising pancreatitis, GIV, and complications of the aforementioned conditions. According to current data, lupus mesenteric vasculitis (LMV) occurs in 10% of patients. Its mortality rate is up to 2.5%, and its prevalence is highest in patients who are in active disease period (2,4). Despite the fact that 10 – 38% of patients with rheumatoid arthritis (RA) have different GI symptoms, only 1% of them develop GIV (15). In patients with primary Sjögren's syndrome (SjS), involvement of the entire GIT is possible. Common symptoms include epigastric pain, dyspepsia and nausea. Other GI manifestations include jejunitis, sigmoiditis, and inflammatory bowel disease (16). Some of the GI presentations of vasculitis include the following: large-vessel vasculitis can cause extensive bowel infarctions as well as infarctions of other organs, while small-vessel vasculitis mostly affects intramural arteries causing focal, segmental ischaemia and ulcerations (8). Despite the increased survival rate of patients with GIV due to advanced treatments (various immunosuppressive therapies and surgical interventions), GI manifestations of AI diseases continue to pose a medical challenge, both in their timely recognition and early care.

The objective of this study was to describe the incidence and clinical manifestations of GIV in patients with various systemic autoimmune (AI) diseases who were treated at the Split University Hospital Centre over a ten-year period.

SUBJECTS AND METHODS

This retrospective cohort study was conducted at the Division of Rheumatology and Clinical Immunology of the Split University Hospital Centre. The patients' medical records were downloaded from the electronic database of the Division of Rheumatology and Clinical Immunology, covering the period from 1 January 2009 to 31 December 2018. Research criteria included anamnestic data on abdominal pain or endoscopic and/or radiographic findings of intestinal vasculitis. GI involvement is defined as GI manifestations present at the time of diagnosis of vasculitis, after other causes of GI symptoms have been ruled out. The aforementioned GI manifestations include: abdominal pain, nausea or vomiting, diarrhoea, bowel obstruction, intussusception, intestinal bleeding, ulceration and perforation, pancreatitis, and bowel infarction. Based on a detailed review of medical records, GIV symptoms were documented in 12 patients. The following diagnostic methods were used in making the diagnosis: multi-slice computed tomography (MSCT), positron emission tomography-computed tomography (PET-CT), endoscopy of the upper gastrointestinal tract, colonoscopy, MR enterography, and histopathology of the GIT mucosa (Table 3). Patients were treated for SLE, SjS, MCTD, IgAV and vasculitis.

ne-nekrotizirajući pankreatitis, GIV te komplikacije navedenih stanja. Prema dosadašnjim podacima, u 10% bolesnika pojavljuje se lupus mezenterični vaskulitis (engl. *lupus mesenteric vasculitis*, LMV) čija je stopa smrtnosti do 2,5%, a prevalencija mu je najviša u onih s aktivnom bolešću (2,4). Unatoč tomu što 10–38% bolesnika s reumatoidnim artritismom (RA) ima različite GI simptome, samo u njih 1% razvija se GIV (15). U bolesnika s primarnim Sjögrenovim sindromom (SjS) moguća je zahvaćenost cijeloga GIT-a. Uobičajeni simptomi su epigastrična bol, dispepsija te mučnina. Ostale GI manifestacije uključuju jejunitis, sigmoiditis te upalnu bolest crijeva (16). Kada sabere-mo GI prezentacije sindroma vaskulitisa, vaskulitisi velikih krvnih žila mogu uzrokovati opsežne intestinalne infarkte, kao i infarkte drugih organa, dok vaskulitisi malih krvnih žila većinom pogađaju intramuralne arterije uzrokujući fokalnu, segmentalnu ishemiju te ulceracije (8). Unatoč sve boljem preživljenju bolesnika s GIV-om zahvaljujući naprednim načinima liječenja (različita imunosupresivna terapija i kirurške intervencije), GI manifestacije AI bolesti i dalje predstavljaju medicinski izazov, kako u njihovom pravovremenom prepoznavanju, tako i u što ranijem zbrinjavanju.

Naš je cilj bio ispitati učestalost i klinička očitovanja crijevnog vaskulitisa u bolesnika s različitim sustavnim AI bolestima liječenih u Kliničkom bolničkom centru Split u desetogodišnjem razdoblju.

ISPITANICI I METODE

Ova retrospektivna studija kohorte provedena je u Zavodu za reumatologiju i kliničku imunologiju KBC-a Split. Medicinski podatci o bolesnicima preuzeti su iz elektronske baze podataka Zavoda, obuhvaćajući vremenski period od 1. siječnja 2009. do 31. prosinca 2018. godine. Kriteriji pretrage uključivali su anamnestičke podatke o boli u trbuhu ili endoskopske ili/i radiografske znakove vaskulitisa crijeva. GI zahvaćenost definirana je kao GI manifestacije prisutne u trenutku dijagnosticiranja vaskulitisa, nakon što su isključeni ostali uzroci GI simptoma. Navedene GI manifestacije odnose se na: bol u trbuhu, mučninu ili povraćanje, proljev, intestinalnu opstrukciju, intususcepciju, intestinalno krvarenje, ulceracije i perforaciju, pankreatitis, infarkt crijeva. Na temelju detaljnog pregleda medicinskih kartona, 12 bolesnika je imalo dokumentirane dokaze GIV-a. Pri postavljanju dijagnoze, korištene su sljedeće dijagnostičke metode: višeslojni CT trbuha (engl. *multi-slice computed tomography*, MS-CT), PET-CT (engl. *positron emission tomography-computed tomography*, PET-CT), endoskopija gornjeg dijela GIT-a, kolonoskopija, MR enterografija, PHD sluznice GIT-a (tablica 3). Bolesnici su se liječili od SLE-a, SjS-a, MCTD-a, IgAV-a i sindroma vaskulitisa.

TABLE 2 Summarised results of the variables of interest in patients with gastrointestinal vasculitis
 TABLICA 2. Zbirni prikaz rezultata parametara od interesa u bolesnika s vaskulitisom gastrointestinalnog trakta

Patient sex and age / Spol i dob bolesnika	Underlying disease / Osnovna bolest	Leading symptom / Vodeći simptom	Endoscopy / Endoskopija	Multi-slice CT / Višeslojni CT	Histopathology finding / PHD	Other methods / Ostale metode	Treatment / Liječenje	Treatment response / Odg. na terapiju
M, 45 years of age / 45. god.	IgAV	Acute abdomen / Akutni abdomen	Hyperemia of the mucous membranes of the oesophagus, stomach and bulbous / Hiperemija sluznice ezofagusa, želuca i bulbosa	Inflammation of jejunal wall / Upala stijenke jejunuma	Ileum: lamina propria permeated with inflammatory infiltrate and eosinophils / Ileum: lamina propria prožeta upalnim infiltratom i eozinofilima	MR enterography: jejunal wall thickening / MR enterografija: zadebljanje stijenke jejunuma	GC / GK, AZA	Good / Dobar
M, 57 years of age / 57. god.	IgAV	Abdominal pain, nausea / Bol u trbuhu, mučnina	Hyperemia of the antrum / Hiperemija antruma	-	-	-	GC / GK	Good / Dobar
M, 64 years of age / 64. god.	IgAV	Acute abdomen / Akutni abdomen	Erosive gastritis / Erozivni gastritis	Inflammation of the wall of the ileum, caecum and ascending colon and sigmoid colon / Upala stijenke ileuma, cekoascendesa i sigme	-	-	GC / GK, AZA	Moderate / Umjeren
M, 44 years of age / 44. god.	IgAV	Abdominal pain / Bol u trbuhu	Gastric hyperemia and erosion / Hiperemija i erozije želuca	-	Mucosa with normal glands / Mukoza s pravilnim žljezdama	-	GC / GK, AZA	Good / Dobar
M, 44 years of age / 44. god.	IgAV	GI bleeding / GI krvarenje	Gastritis and duodenitis, mucosal hyperemia / Gastroduodenitis, hiperemija sluznice	-	-	-	GC, chloroquine / GK, KLOROKIN	Good / Dobar
M, 22 years of age / 22. god.	IgAV	Abdominal pain / Bol u trbuhu	Hyperemia of the gastric mucosa / Hiperemija sluznice želuca	-	-	-	GC / GK	Good / Dobar
M, 20 years of age / 20. god.	IgAV	Abdominal pain, vomiting / Bol u trbuhu, povraćanje	Hyperemic mucosa of the antrum / Hiperemična sluznica antruma	-	-	-	GC / GK	Good / Dobar
M, 60 years of age / 60. god.	IgAV	Acute abdomen / Akutni abdomen	Erosive gastritis / Erozivni gastritis	Dilated small bowel loops with closed loop torsion / Dilatirane vijuge TC-a, torzija, „Cloosed loop“	-	-	GC / GK, AZA	Moderate / Umjeren

TABLE 2 Continued
TABLICA 2. Nastavak

Patient sex and age / Spol i dob bolesnika	Underlying disease / Osnovna bolest	Leading symptom / Vodeći simptom	Endoscopy / Endoskopija	Multi-slice CT / Višeslojni CT	Histopathology finding / PHD	Other methods / Ostale metode	Treatment / Liječenje	Treatment response / Odg. na terapiju
F / Ž, 23 years of age / 23. god.	SLE	Acute abdomen / Akutni abdomen	Erosive gastritis / Erozivni gastritis	Stratification of the bowel wall / Raslojavanje stijenke crijeva	Jejunum: mucosal necrosis, inflammatory infiltrate and submucosal haemorrhage / Jejunum: nekroza sluznice, upalni infiltrat i krv podsluznice	-	GC / GK, CYC, IVIG	Adverse / Nepovoljan
F / Ž, 31 years of age / 31. god.	SLE	GI bleeding / GI krvarenje	Hyperemic mucosa of the antrum, erosions / Hiperemija sluznice antruma, erozije	-	-	-	GC / GK, CYC	Good / Dobar
F / Ž, 54 years of age / 54. god.	MPA	No symptoms / Bez simptoma	-	-	-	PET-CT: FDG uptake in the colon / PET-CT: signal FDG duž crijeva	GC / GK, AZA, MTX, CYC, RTX	Moderate / Umjeren
M, 78 years of age / 78. god.	Primary SS / primarni SS	Acute abdomen / Akutni abdomen	-	Congestion and mesenteric oedema / Kongestija i edem mezenterija	-	-	GC / GK, CYC, IVIG	Moderate / Umjeren

Legend / Legenda: CT – computed tomography; PHD – histopathology diagnosis / patohistološka dijagnostika; MR – magnetic resonance / magnetska rezonancija; IgAV – IgA vasculitis / IgA-vaskulitis; SLE – systemic lupus erythematosus / sistemski eritemski lupus; MPA – microscopic polyangiitis / mikroskopski poliangitis; SS – Sjögren's syndrome / Sjögrenov sindrom; GI – gastrointestinal / gastrointestinalna; GC / GK – glucocorticoid / glukokortikoid; AZA – azathioprine / azatioprin; CYC – cyclophosphamide / ciklofosfamid; IVIG – intravenous immunoglobulins / intravenski imunoglobulini; RTX – rituximab / rituksimab.

In terms of descriptive statistics methods for statistical analysis, an arithmetic mean with standard deviation or a median with interquartile range for continuous variables were used, as well as frequency (percentages) for categorical variables. The analysis was performed using the MedCalc computer programmes (MedCalc Software, Ostend, Belgium).

RESULTS

The diagnosis of gastrointestinal vasculitis was confirmed in 12 patients, of whom 9 were men (75%). The median age at diagnosis of GIV was 45.2 ± 23.3 years. The results of our research are summarised in Table 2. Eight patients (67%) had GIV in IgAV. Other patients with vasculitis also had underlying conditions such as SLE (2 patients), MPA (1 patient), and primary SS (1 patient). The leading symptom in four patients was abdominal pain with nausea and vomiting, 2 patients had profuse GI bleeding, one patient had fatigue without GI symptoms, and the remaining patients' clinical features included acute abdomen with visible radiographic thickening of the bowel wall with oedema and stratification with ascites. Diagnostic methods are listed in Table 3. In six (50%) cases, vasculitis was detected by an MSCT of the abdomen (three patients with IgAV, two patients with SLE, one patient with SS), in one case it was detected by a PET-CT scan, in one case through histopathological findings, and in four cases through endoscopic findings. CT of the abdomen showed thickening and stratification of the bowel wall, followed by inflammation of the wall of the jejunum, ileum, caecum and ascending colon and sigmoid colon, and dilated bowel loops (Figure 1). In one patient, CT showed congestion and mesenteric oedema (Figure 1). Endoscopy of the upper GIT was performed in 10 (83%) patients, and abnormalities were detected in all of them. The abnormalities were mostly related to hyperemia and mucosal erosions (Figure 1). In one patient with IgAV, MR enterography was subsequently performed through which jejunal loops with bowel wall thickening along with a misty mesentery sign with swollen lymph nodes were detected (Figure 1). Finally, GI biopsies were performed in three patients, and a pathological finding was detected in two of them. Inflammatory infiltrate of the lamina propria of the ileum was detected in a patient with IgAV, and in a patient with SLE who died as a result of GIV, gangrene of the small intestine with acute peritonitis (mucosal necrosis of the jejunum with accumulation of mixed inflammatory infiltrate and blood in lamina propria and bleeding through the rest of the wall with thrombotic microangiopathy and fibrinoid necrosis of the blood vessels) was detected (Figure 1).

All patients were treated with glucocorticoids (GCs) (methylprednisolone administered intravenously or a

Za statističku analizu od metoda deskriptivne statistike korištena je aritmetička sredina sa standardnom devijacijom ili medijan s interkvartilnim rasponom za kontinuirane varijable te frekvencija (postotci) za kategorijske varijable. Korišten je računalni program *MedCalc* (*MedCalc Software*, Ostend, Belgium).

REZULTATI

U 12 bolesnika je potvrđena dijagnoza crijevnog vaskulitisa, od čega su 9 bili muškarci (75%). Srednja životna dob pri postavljanju dijagnoze GIV-a iznosila je $45,2 \pm 23,3$ godina. Rezultati našeg istraživanja zbirno su prikazani u tablici 2. Osam bolesnika (67%) imalo je GIV u sklopu IgAV-a. U ostalim vaskulitisima, u podlozi je bio SLE (2 bolesnice), MPA (1 bolesnica), primarni SS (1 bolesnik). Vodeći simptom u četvero bolesnika bila je bol u trbuhu s mučninom i povraćanjem, dvojica su imala obilno GI krvarenje, jedna bolesnica je imala umor bez simptoma od strane GI sustava, a preostalih pet bolesnika kliničku sliku akutnog abdomena s radiološki verificiranim edemom i raslojavanjem stijenke crijeva uz ascites. Dijagnostičke metode prikazane su u tablici 3. U šest (50%) slučajeva vaskulitis je dokazan MS-CT-om trbuha (tri bolesnika s IgAV-om, dvije bolesnice sa SLE-om, jedan bolesnik sa SS-om), u jednom PET-CT-om, u jednom patohistološki, a u četiri slučaja endoskopski. CT-om trbuha prikazana su zadebljanja i raslojavanje stijenke crijeva, potom upala stijenke jejunuma, ileuma, cekoascendensa i sigme te dilatirane crijevne vijuge (slika 1). U jedne bolesnice CT-om se prikazala kongestija i edem mezenterija (slika 1). Endoskopija gornjeg dijela GIT-a izvršena je u 10 (83%) bolesnika, i kod svih su uočene abnormalnosti, većinom hiperemija i erozija sluznice (slika 1). U jednog bolesnika s IgAV-om naknadno je učinjena i MR enterografija kojom su se utvrdile zadebljane stijenke vijuge jejunuma uz zamućen mezenterij s uvećanim limfnim čvorovima (slika 1). Naposljetku, GI biopsije su obavljene u tri bolesnika, otkrivši patološki nalaz u dva. U bolesnika s IgAV-om dokazan je upalni infiltrat lamine proprije ileuma, a u bolesnice sa SLE-om, koja je preminula od posljedica GIV-a, utvrđena je gangrena tankog crijeva s akutnim peritonitisom (nekrotična sluznica jejunuma uz kolekciju miješanoga upalnog infiltrata i krvi u lamini propriji te krvarenja kroz ostatak stijenke uz trombotičnu mikroangiopatiju i fibrinoidnu nekrozu krvnih žila) (slika 1).

Svi bolesnici su liječeni GK (intravenskim metilprednizolonom ili peroralno prednizonom u dozi od 0,5 do 1 mg/kg) uz postupnu redukciju doze. Početna doza metilprednizolona od 80 mg ordinirana je u osam bolesnika (pet bolesnika s IgAV-om, dvije bolesnice sa SLE-om te u bolesnika s SS-om). U preostalih četvero

dose of 0.5 – 1 mg/kg of prednisone administered orally) with gradual dose reduction. An initial dose of methylprednisolone of 80 mg was administered to eight patients (five patients with IgAV, two patients with SLE, and one patient with SS). In the remaining four patients, treatment was initiated with a dose of prednisone of 60 mg, administered orally (three patients with IgAV and one patient with MPA). In four patients with IgAV, azathioprine (AZA) at a dose of 150 mg/day was introduced, and in one patient chloroquine (250 mg/day) was introduced. Other patients with IgAV had an excellent response to treatment with moderate doses of GCs. In patients with SLE, in addition to GC therapy, cyclophosphamide therapy was administered (CYC) at a dose of 500 mg/m² of body surface area, and in one patient intravenous immunoglobulins therapy was administered (IVIG) at a dose of 0.4 mg/kg. CYC and IVIG therapy was administered to patients with SS as well, at the same doses as in patients with SLE. A satisfactory response to treatment was achieved in three patients; however, one patient with SLE died as a result of mesenteric vasculitis (after repeated surgical interventions – bowel resection). A patient with MPA who was treated with all of the aforementioned drugs had a satisfactory response to treatment (Table 2).

DISCUSSION

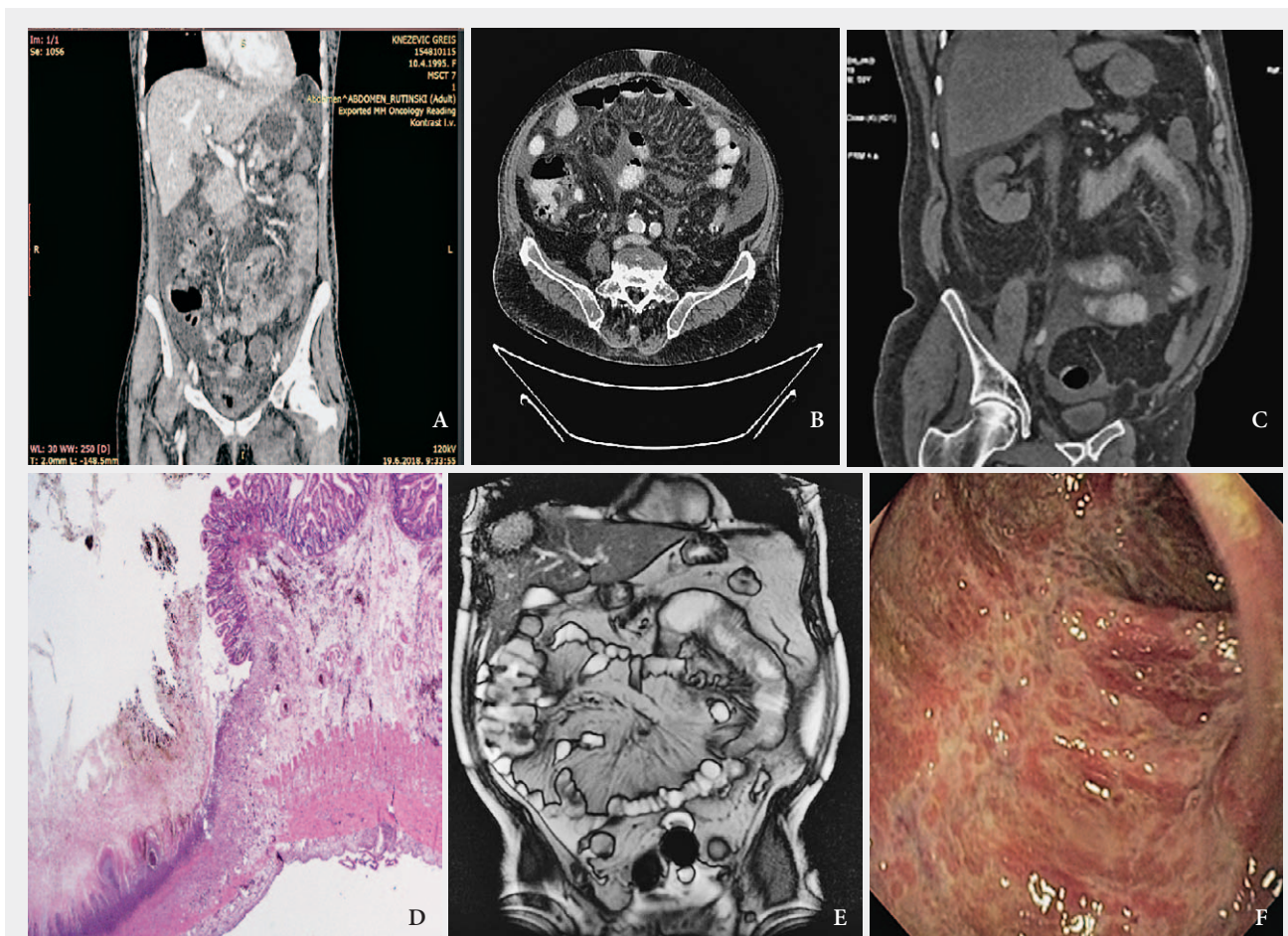
The treatment of patients with GIV in systemic AI diseases still poses a serious challenge because GI system involvement is a rare but very serious complication of the underlying disease that can significantly affect its possible outcomes. Given that clinical symptoms are very diverse and non-specific, and that abdominal pain may be the first, early symptom of bowel perforation, rheumatologists should always approach patients who report newly occurring GI complications with caution (1). To the best of our knowledge, no controlled randomised clinical trials have been conducted on this topic. All data were obtained from a series of case reports, retrospective studies, and a systematic literature review. If GIV presents with clinical features of acute abdomen or GI bleeding, the recommendation for treatment is the use of GCs as the first-line therapy with some of the following immunosuppressants: cyclophosphamide (CYC), methotrexate (MTX), azathioprine (AZA), intravenous immunoglobulins (IVIG), rituximab (RTX), chloroquine (1,2,4). The results of our study showed that GIV most often occurs in IgAV and has the best response to therapy, which is consistent with most data to date (11,12). Remission was achieved in most patients and GIT involvement was not associated with an adverse outcome and relapse of IgAV, which is inconsistent with the results of another study in which GI involvement at the time of diagno-

TABLE 3. Diagnostics of gastrointestinal vasculitis
TABLICA 3. Dijagnostika vaskulitisa gastrointestinalnoga trakta

Diagnostic methods / Dijagnostičke metode	GI patients / GI bolesnici (N=12)
Multi-slice CT / Višeslojni CT	5
Small bowel wall inflammation / Upala stijenke tankog crijeva	2
Dilatation small bowel wall with torsion / Dilatacija stijenke tankog crijeva uz torziju	1
Stratification of the bowel wall / Raslojavanje stijenke crijeva	1
Congestion and mesenteric oedema / Kongestija i edem mezenterija	1
MR enterography / MR enterografija	1
Jejunum wall thickening / Zadebljanje stijenke jejunuma	1
PET-CT	1
FDG uptake in the colon / Signal FDG duž crijeva	1
Endoscopy of the upper GIT / Endoskopija gornjeg GIT-a	10
Hyperemia and mucosal erosions / Hiperemija sluznice i erozije	7
Erosive gastritis / Erozivni gastritis	3
Histological finding / Histološki nalaz	3
No abnormalities detected / Uredan nalaz	1
Infiltration of inflammatory cells and eosinophils / Infiltracija upalnih stanica i eozinofila	1
Infiltration of inflammatory cells with vascular fibrosis / Infiltracija upalnim stanicama uz fibrozu krvnih žila	1

Legend / Legenda: CT – computed tomography; MR – magnetic resonance / magnetska rezonanca; PET-CT / PET CT – positron emission tomography with computed tomography / pozitronska emisijska tomografija s kompjutoriziranom tomografijom; FDG – fluorodeoxyglucose / fluorodeoksiglukoza; GIT – gastrointestinal tract / gastrointestinalni trakt.

bolesnika liječenje je započeto s peroralnom dozom prednizona od 60 mg (tri bolesnika s IgAV-om te jedna bolesnica s MPA-om). U četvero bolesnika s IgAV-om, uz redukciju doze GK, u terapiju se uveo azatioprin (engl. *azathyoprin*, AZA) u dozi od 150 mg dnevno, a u jednog bolesnika klorokin (250 mg/dn). Ostali bolesnici s IgAV-om postigli su odličan odgovor na liječenje samo sa srednjim dozama GK. U bolesnica sa SLE-om, uz GK, provedena je terapija ciklofosfamidom (engl. *cyclophosphamide*, CYC) u dozi od 500 mg/m² tjelesne površine, a u jedne i intravenskim imunoglobulinima (engl. *intravenous immunoglobulin*, IVIG) u dozi od 0,4 mg/kg tjelesne težine. Terapija s CYC-om i IVIG-om u istim dozama kao i u SLE-u ordinirana je



Legend / Legenda: a) multi-slice CT of GIV in patient with SLE shows oedema and stratification of the bowel wall (target sign) / višeslojni CT GIV-a u bolesnice sa SLE-om prikazuje edemi i raslojavanje stijenke crijeva (target sign); b) multi-slice CT in patient with SS shows free fluid perihepatic space, perisplenic space, paracolic gutter and interstitial space with mesenteric congestion / višeslojni CT u bolesnika sa SS-om prikazuje slobodnu tekućinu perihepatalno, perispenično, parakolično i interstinalno uz kongestiju mezenterija; c) multi-slice CT in patient with IgAV shows dilated small bowel loops with torsion and congestion of the associated mesentery; two transition points collapsed into dilated loops: closed loop / višeslojni CT u bolesnika s IgAV-om prikazuje dilatirane vijuge TC uz torziju istih i kongestiju pripadajućeg mezenterija; dva prelaska kolabiranih u dilatirane vijuge: „closed loop”; d) small bowel histopathology in patient with SLE (hematoxylin and eosin staining, 20x magnification) shows full-thickness necrosis of the bowel wall, as well as complete necrosis of serosa / PHD tankog crijeva u bolesnice sa SLE-om (bojenje hemalaunom i eozinom, povećanje 20x) prikazuje nekrotičnu stijenk u cijeloj debljini, kao i potpunu nekrozu seroze; e) MR enterography of the GIV in patient with IgAV shows jejunal loops with bowel wall thickening; one of the loops is fixed; misty mesentery sign with swollen lymph nodes / MRI entrografija GIV-a u bolesnika s IgAV-om prikazuje vijuge jejunuma zadebljane stijenke; jedna od vijuga fiksirana; mezenterij zamućen s uvećanim limfnim čvorovima; f) endoscopy of the upper GIT in patients with IgAV shows hyperemia and mucosal erosion / endoskopija gornjeg dijela GIT-a u bolesnika s IgAV-om prikazuje hiperemiju i eroziju sluznice.

FIGURE 1. Imaging (different techniques) of gastrointestinal vasculitis in patients with autoimmune diseases
SLIKA 1. Slikovni prikaz (različite tehnike) gastrointestinalnoga vaskulitisa u bolesnika s autoimunim bolestima

sis, along with joint involvement, was associated with more frequent relapses. The reason for this is the impartiality in the selection of subjects in this study (children and adults, cutaneous, renal and joint manifestations of the disease, different treatment protocols) (17). In our study, the subjects were individuals ≥ 18 years of age with predominantly cutaneous and GI symptoms who had a good response to treatment, i.e., who have achieved remission. With regard to GIV in SLE, lupus mesenteric vasculitis (LMV) is known to occur in up to 10% of patients, with the highest prevalence being in

i u bolesnika sa SS-om. U tri bolesnika postignut je zadovoljavajući odgovor na liječenje, međutim jedna bolesnica sa SLE-om je preminula od posljedica mezenterijalnog vaskulitisa (nakon opetovanih operativnih zahvata – resekcije crijeva). U bolesnice s MPA provedena je terapija svim navedenim lijekovima sa zadovoljavajućim odgovorom (tablica 2).

RASPRAVA

Zbrinjavanje bolesnika s GIV-om u sklopu sistemskih AI bolesti i dalje predstavlja pravi izazov zbog toga

patients in active disease period. Typical manifestations of lupus enteritis include focal or diffuse thickening of the bowel wall, bowel dilatation, and ascites, which provide visible radiographic signs such as the "target sign" and "comb sign": increased bowel wall volume, thickening and multiplication of mesenteric blood vessels, and high adipose tissue density. First-line therapy includes administration of high doses of GCs, administered intravenously, and in refractory cases CYC therapy is administered as well. In patients with obvious signs of peritonitis and highly suspected intestinal perforation or ischaemia, surgical treatment should not be delayed (18). In one of our patients, all the aforementioned treatment methods were used with IVIG, but there was a fatal outcome, while in other patients a good response to treatment was achieved. According to data found in literature, the prognosis of LMV varies and depends on the extent of ischaemia, and better outcomes can be achieved with early administration of high doses of GCs, CYC, or RTX (19). In patients with primary SS, systemic vasculitis extremely rarely affects the GIT, and it may be linked to associated cryoglobulinemia. If ischaemia or bowel infarction are present, the condition is life-threatening. If GC therapy or immunosuppressants prove to be inefficient, surgical intervention is required (20). GIT is rarely affected in MPA; however, it is a very serious manifestation of the disease with possible severe consequences. Although there are no clear treatment recommendations, intravenous GCs with immunosuppressants (CYC or RTX) are administered in most cases (21). Survival rates differ in various studies, but recent data suggest that mortality is the same in patients with MPA regardless of GI tract involvement (21–23).

Patients with GIV who were treated in our university hospital centre had a good response to treatment and the outcome was fatal in only one patient. We believe that the reason for the favourable outcomes is the timely diagnosis and rapid therapeutic intervention, but longer follow-ups with more subjects are required in order to find out whether the survival rate has really improved over the last few years. Since these are rare disorders, successful treatment of these patients requires a range of diagnostic and laboratory procedures, as well as good cooperation between experts in a multidisciplinary team (rheumatologists, gastroenterologists, radiologists, pathologists and surgeons). Diagnosis is made based on clinical suspicion and imaging methods because there is no specific test for the detection of GIV in systemic AI diseases.

Our study is limited due to retrospective nature of data collection, which is why there are certain shortcomings. In addition to that, other limitations include the relatively small number of patients and the fact that

što je zahvaćenost GI sustava rijetka, ali vrlo ozbiljna komplikacija osnovne bolesti koja može značajno utjecati na ishod. S obzirom na to da su klinički simptomi vrlo raznoliki i nespecifični te kako bol u trbuhu može biti prvi, rani simptom perforacije crijeva, reumatolozi uvijek s oprezom trebaju pristupiti bolesnicima koji navode novonastale GI smetnje. (1) Prema našim saznanjima do sada nije provedeno ni jedno kontrolirano randomizirano kliničko ispitivanje na navedenu temu. Svi podatci dobiveni su iz serija prikaza slučajeva, retrospektivnih studija i sustavnog pregleda literature. Ukoliko se GIV prezentira kliničkom slikom akutnog abdomena ili GI krvarenjem, preporuka za liječenje je primjena GK kao prve linije uz neki od immunosupresivnih lijekova: ciklofosamid (engl. *cyclophosphamide*, CYC), metotreksat (engl. *methotrexate*, MTX), AZA, IVIG, rituksimab (engl. *rituximab*, RTX), klorokin (1,2,4). Rezultati naše studije pokazali su kako se GIV najčešće javlja u sklopu IgAV-a te ima najbolji odgovor na terapiju, što je u skladu s većinom dosadašnjih podataka (11,12). U većine bolesnika postignuta je remisija te zahvaćenost GIT-a nije bila povezana s lošijim ishodom i relapsom IgAV-a, što se pak ne podudara s rezultatima jednoga drugog istraživanja u kojem je zahvaćenost GI sustava u trenutku postavljanja dijagnoze, zajedno sa zglobnom zahvaćenošću, bila povezana s češćim relapsom. Razlog navedenome je nepristranost pri izboru ispitanika u navedenom istraživanju (djeca i odrasli, kožne, bubrežne i zglobne manifestacije bolesti, različiti protokoli liječenja) (17). U našem istraživanju ispitanici su bili osobe ≥ 18 godina s dominantno kožnim i GI simptomima s dobrim odgovorom na provedeno liječenje, odnosno postizanjem remisije. Što se tiče GIV-a u sklopu SLE-a, poznato je da se LMV javlja u do 10% bolesnika, s najvišom prevalencijom u bolesnika s aktivnom bolešću. Tipična obilježja lupusnog enteritisa uključuju fokalno ili difuzno zadebljanje stijenke crijeva, dilataciju crijeva i ascites koji daju prepoznatljiva radiološka obilježja „znak mete“ i „znak češlja“ (engl. *target and comb's signs*): povećani volumen stijenke crijeva, zadebljanje i umnažanje mezenterijalnih krvnih žila i povišeni denzitet masnoga tkiva. Prva linija liječenja su visoke doze intravenskih GK, a za refraktorne slučajeve primjenjuje se i CYC. U bolesnika s očitim znakovima peritonitisa i visokom sumnjom na perforaciju ili ishemiju crijeva kirurški pristup se ne smije odgađati (18). U jedne naše bolesnice provedene su sve navedene mjere liječenja uz IVIG-e, međutim došlo je do smrtnog ishoda, dok je u druge bolesnice postignut dobar odgovor na provedeno liječenje. Prema literaturnim podacima, prognoza LMV-a varira i ovisi o opsegu ishemije, a bolji ishodi se mogu postići ranom primjenom visokih doza GK, CYC-a ili RTX-a (19). U bolesnika s pri-

this study was conducted in a single hospital centre. Despite the descriptive analysis, with all the inherent bias associated with this type of research, we have tried to gain useful insights in order to improve the identification and treatment of patients with GIV in various AI diseases.

CONCLUSION

GIV is a rare manifestation of systemic AI diseases, but the clinical features can be very severe and lead to a fatal outcome, especially if it is not diagnosed at an early stage and treated with aggressive immunosuppressive therapy. However, additional studies are needed to identify factors that influence the prognosis and treatment outcome of these disorders, as well as clear recommendations and guidelines for the treatment of these patients.

Acknowledgement

The authors would like to thank the staff of the Division of Gastroenterology at the Department of Internal Medicine, Split University Hospital Centre, especially Žarko Ardalić, MD, as well as the staff of the Department of Diagnostic and Interventional Radiology, Split University Hospital Centre, especially Krešimir Bukarica, MD, and Ana Dunatov Huljev, MD from the Department of Pathology, Forensic Medicine and Cytology, Split University Hospital Centre.

CONFLICT OF INTEREST STATEMENT: The authors declare no conflict of interest.

marnim SS-om, sistemski vaskulitis iznimno rijetko zahvaća GIT, i može ga se povezati s pridruženom krioglobulinemijom. Ako su prisutni ishemija ili infarkt crijeva, stanje je opasno po život. Ukoliko se terapijom GK ili imunosupresivima ne postigne učinak, potreban je kirurški zahvat (20). GIT je rijetko zahvaćen u MPA, međutim radi se o vrlo ozbiljnoj manifestaciji bolesti s moguće teškim posljedicama. Iako ne postoje jasne preporuke za liječenje, većinom se primjenjuju intravenski GK s imunosupresivima (CYC ili RTX) (21). Stopa preživljenja se razlikuje u nekoliko studija, ali noviji podatci ukazuju kako je smrtnost jednaka u bolesnika s MPA bez obzira na zahvaćenost GI trakta (21-23).

Bolesnici s GIV-om u našem centru imali su dobar odgovor na provedeno liječenje te je u samo jednom slučaju došlo do smrtnog ishoda. Mišljenja smo kako je razlog dobrim ishodima pravodobno postavljanje dijagnoze i brza terapijska intervencija, ali potrebna su dulja praćenja s većim brojem ispitanika koja bi pokušala odgovoriti je li zaista poboljšana stopa preživljenja tijekom posljednjih nekoliko godina. Budući da se radi o rijetkim poremećajima, za uspješno liječenje ovih bolesnika potreban je čitav niz dijagnostičkih i laboratorijskih postupaka, kao i dobra suradnja multidisciplinarnog tima (reumatolozi, gastroenterolozi, radiolozi, patolozi i kirurzi). Dijagnoza se postavlja temeljem kliničke sumnje i slikovnih metoda jer ne postoji nijedna specifična pretraga za dokazivanje GIV-a u sklopu sistemskih AI bolesti.

Ograničenje našeg istraživanja jest retrospektivnost prikupljanja podataka, zbog čega postoje određene nedostatnosti. Također, ograničenja su i relativno mali uzorak bolesnika te provođenje istraživanja u samo jednom centru. Unatoč deskriptivnoj analizi, uza svu inherentnu pristranost koja se veže uz takvu vrstu istraživanja, pokušali smo izvući korisne spoznaje u svrhu poboljšanja prepoznavanja i liječenja bolesnika s GIV-om u sklopu različitih AI bolesti.

ZAKLJUČAK

Crijevni vaskulitis je rijetka manifestacija sistemskih AI bolesti, ali klinička slika može biti vrlo teška i dovesti do fatalnog ishoda te je nužna brza dijagnoza i agresivno imunosupresivno liječenje. Međutim, dodatne studije su nužne kako bi se identificirali čimbenici koji utječu na prognozu i ishod liječenja ovih poremećaja, kao i jasne preporuke i smjernice za zbrinjavanje ovih bolesnika.

Zahvale

Autori zahvaljuju osoblju Zavoda za gastroenterologiju Klinike za unutarnje bolesti, posebno dr. Žarku Ardaliću, osoblju Kliničkoga zavoda za dijagnostičku i

REFERENCES / LITERATURA

1. Cojocaru M, Cojocaru IM, Silosi I, Vrabie CD. Gastrointestinal manifestations in systemic autoimmune diseases. *Maedica (Bucur)*. 2011;6(1):45–51.
2. Ahn E, Luk A, Chetty R, Butany J. Vasculitides of the gastrointestinal tract. *Semin Diagn Pathol*. 2009;26(2):77–88.
3. Jennette JC, Falk RJ, Bacon PA, Basu N, Cid MC, Ferrario F i sur. 2012 revised international Chapel Hill Consensus conference nomenclature of vasculitides. *Arthritis Rheum*. 2013;65(1):1–11.
4. Chetty R, Serra S. A pragmatic approach to vasculitis in the gastrointestinal tract. *J Clin Pathol*. 2017;70(6):470–5.
5. Jennette JC, Falk RJ, Andrassy K, Bacon PA, Churg J, Gross WL i sur. Nomenclature of systemic vasculitides. Proposal of an international consensus conference. *Arthritis Rheum*. 1994;37(2):187–92.
6. Jennette JC, Falk RJ. Small-vessel vasculitis. *N Engl J Med*. 1997;337(21):1512–23.
7. Ha HK, Lee SH, Rha SE, Kim JH, Byun JY, Lim HK i sur. Radiologic features of vasculitis involving the gastrointestinal tract. *Radiographics*. 2000;20(3):779–94.
8. Soowamber M, Weizman AV, Pagnoux C. Gastrointestinal aspects of vasculitides. *Nat Rev Gastroenterol Hepatol*. 2017;14(3):185–94.
9. Schmidt J, Kermani TA, Bacani AK, Crowson CS, Cooper LT, Matteson EL i sur. Diagnostic features, treatment, and outcomes of Takayasu arteritis in a US cohort of 126 patients. *Mayo Clin Proc*. 2013;88(8):822–30.
10. Colomba C, La Placa S, Saporito L, Corsello G, Ciccia F, Medaglia A i sur. Intestinal Involvement in Kawasaki Disease. *J Pediatr*. 2018;202:186–93.
11. Audemard-Vergier A, Pillebout E, Guillevin L, Thervet E, Terrier B. IgA vasculitis (Henoch–Schönlein purpura) in adults: diagnostic and therapeutic aspects. *Autoimmun Rev*. 2015;14(7):579–85.
12. Pillebout E, Verine J. Henoch–Schönlein purpura in the adult. *Rev Med Interne*. 2014;35(6):372–81.
13. Vaiopoulos AG, Sfikakis PP, Kanakis MA, Vaiopoulos G, Kaklamani PG. Gastrointestinal manifestations of Behçet's disease: advances in evaluation and management. *Clin Exp Rheumatol*. 2014;32:140–8.
14. Zeidan MJ, Saadoun D, Garrido M, Klatzmann D, Six A, Cacoub P. Behçet's disease physiopathology: a contemporary review. *Auto Immun Highlights*. 2016;7(1):4.
15. Bartels C, Bell C, Rosenthal A, Shinki K, Bridges A. Decline in rheumatoid vasculitis prevalence among US veterans: a retrospective cross-sectional study. *Arthritis Rheum*. 2009;60(9):2553–7.
16. Asherson R, Font J, Ramos-Casals M, Rodes J. Digestive involvement in systemic autoimmune diseases. U: Asherson R, ur. *Handbook of systemic autoimmune diseases*. Amsterdam: Elsevier Ltd.; 2008, str. 1–295.
17. Calvo-Río V, Hernández JL, Ortiz-Sanjuán F, Loricera J, Palmou-Fontana N, González-Vela MC i sur. Relapses in patients with Henoch–Schönlein purpura: Analysis of 417 patients from a single center. *Medicine (Baltimore)*. 2016;95(28):e4217.
18. Yuan S, Ye Y, Chen D, Qiu Q, Zhan Z, Lian F i sur. Lupus mesenteric vasculitis: clinical features and associated factors for the recurrence and prognosis of disease. *Semin Arthritis Rheum*. 2014;43(6):759–66.
19. Hatemi I, Hatemi G, Çelik AF. Systemic vasculitis and the gut. *Curr Opin Rheumatol*. 2017;29(1):33–8.
20. Doyle MK. Vasculitis associated with connective tissue disorders. *Curr Rheumatol Rep*. 2006;8(4):312–6.
21. Eriksson P, Segelmark M, Hallböök O. Frequency, Diagnosis, Treatment, and Outcome of Gastrointestinal Disease in Granulomatosis with Polyangiitis and Microscopic Polyangiitis. *J Rheumatol*. 2018;45(4):529–37.
22. Mahr A, Katsahian S, Varet H, Guillevin L, Hagen EC, Höglund P i sur. Revisiting the classification of clinical phenotypes of anti-neutrophil cytoplasmic antibody-associated vasculitis: a cluster analysis. *Ann Rheum Dis*. 2013;72(6):1003–10.
23. Guillevin L, Lhote F, Gayraud M, Cohen P, Jarrousse B, Lortholary O i sur. Prognostic factors in polyarteritis nodosa and Churge-Strauss syndrome. A prospective study of 342 patients. *Medicine (Baltimore)*. 1996;75(1):17–28.

intervenciju radiologiju, posebno dr. Krešimiru Bukarici te dr. Ani Dunatov Huljev s Kliničkog zavoda za patologiju, sudsku medicinu i citologiju.

IZJAVA O SUKOBU INTERESA: Autori izjavljuju da nisu u sukobu interesa.